

Rare cases of ectopic pregnancy in Alice Springs

R Bansal, Halliday M, Lyngdoh BT, Lakshmi J

Ovarian ectopic

Random event

1:7000 pregnancies

Risk factors- IVF & LNG IUD

Spiegelberg's criteria

Management:

- . Medical: Methotrexate
- . Surgical: Oophorectomy (partial or complete)

Cornual/interstitial Ectopic

Difficult early detection

Challenging and most Hazardous type

1-3 percent of all ectopics

Risk factors- PID/IVF/previous ectopic

Diagnosis- TVS –“interstitial line sign” Or

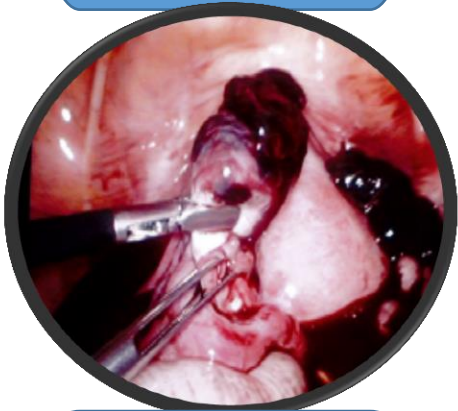Intra-op

Management:

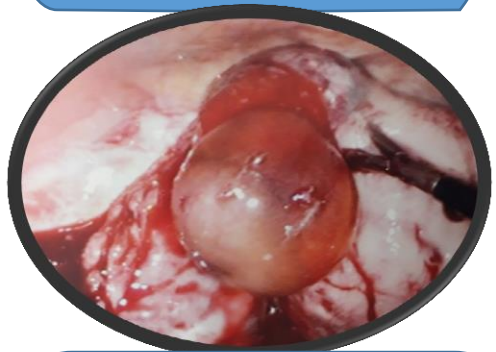
Medical: Methotrexate

Surgical: Cornual resection or

Hysterectomy



28 yr., Mirena insertion
1 year back with 2 litre
haemo peritoneum



38 yr., RFDS from Willowra,
G5P4 previous 3 CS with 10 weeks live
pregnancy, minimal free fluid in POD

These rare cases were diagnosed and managed
laparoscopically in Alice Springs hospital and
thus provided safe and less morbid
management to our patients.