



# An abnormally invasive placenta complicating a mid trimester abortion; a case report

J De Bortoli, D Epitawela

The Royal Women's Hospital, Parkville VIC

## Background

Placenta adhesive disorders (PAD) are an uncommon condition characterised by an abnormally invasive placenta (AIP) according to depth of invasion of the chorionic villi beyond the decidua basalis. Prenatal evaluation of the placenta routinely occurs during the 2<sup>nd</sup> & 3<sup>rd</sup> trimesters.

## Case Summary

42yo G8P4+1 underwent routine mid trimester abortion at 16/40 with misoprostol, dilatation and evacuation under US guidance in April 2016.

### History:

- Smoker, Anxiety, Depression
- x3 Vaginal Births, x1 LUSCS (Twins)
- x2 STOP, x1 Spontaneous miscarriage

The procedure was complicated by 1000mls blood loss

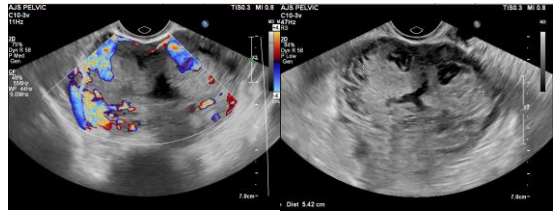


Figure 1: Sonographic features of AIP

She re-presented in May 2016 complaining of vaginal bleeding. Pelvic US demonstrated sonographic features of PAD (Fig 1)

- RPOC 40x40x27mm
- Invading into the myometrium
- Hypervascular flow & surrounding inflammatory mass

In June 2016 she underwent uncomplicated Total Abdominal Hysterectomy + Bilateral Salpingectomy.

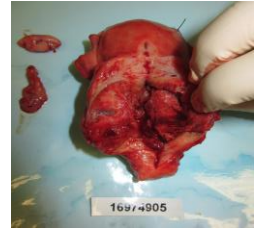


Figure 2: Pathology specimen

Histopathology confirmed presence of retained necrotic tissue associated with a CS Scar extending through the wall to abut the serosa, consistent with placenta increta (Fig 2)

## Discussion

The incidence of PAD is increasing globally and its association with several major maternal complications contributes to higher rates of maternal morbidity and mortality.

### Risk Factors:

- Increased maternal age
- Smoking
- Multiparity
- Previous uterine surgery
- Curettage
- Uterine ablation or irradiation
- Asherman's syndrome
- Fibroids or anomalies
- Placenta Praevia
- Caesarean Section Scar

Prenatal diagnosis of an AIP is advantageous for pre-planned management strategies to reduce this associated burden.

- Currently occurs with US/MRI in 2<sup>nd</sup> & 3<sup>rd</sup> Trimesters of pregnancy
- Investigation of the placenta earlier than this is currently not part of routine practice

A recent review found US signs suggestive of an AIP are already present during the 1<sup>st</sup> trimester. They found  $\geq 1$  US sign suggestive of an AIP in 91.4% of cases, most commonly low implantation of the gestational sac close to a previous uterine scar observed in 82% of cases. Other features included placental lacunae (46%) & myometrial thickness (66%).

## Conclusion

This case demonstrates the ability of an AIP to complicate a pregnancy at any gestation. Considering invasion occurs from early pregnancy, should we investigate women with risk factors earlier for signs of a PAD? We need further investigation with prospective analysis of women at risk to determine if imaging for placental invasion in early pregnancy may be of clinical use.