



# An Unusual Case of Unilateral Absent Infundibulopelvic Ligament

Ho XY, MBBS, MRCOG

Khong CC, MBBS, M.Med.(O&G), AMEC (Aust), FAMS, FRCOG, FRANZCOG

## Introduction

During laparoscopy, pelvic anatomical variations<sup>1</sup> may be expected but an absent infundibulopelvic ligament with present bilateral adnexa has not been reported in the literature thus far.

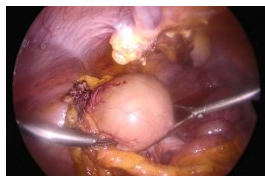
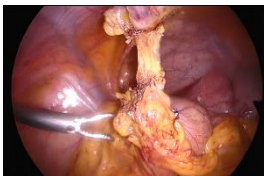An absent infundibulopelvic ligament with present ipsilateral ovary is a very interesting discovery during a diagnostic laparoscopy because it defies our understanding of embryological development and vasculature.

## Patient History

A 33 year old lady presented to our clinic for primary infertility. She has no past medical history or surgeries before. She was asymptomatic and her periods were regular with no dysmenorrhea, dyschezia or dyspareunia.

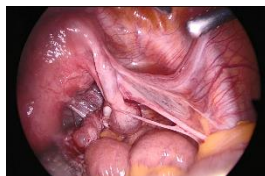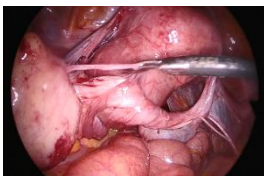
On investigation, her partner's semen analysis was normal and she was having ovulatory cycles. Her ultrasound pelvis showed an ovarian cyst and thickened endometrium with evidence of a 1.2cm polyp. Hence she was listed for a diagnostic laparoscopy, cystectomy, hysteroscopic polypectomy and hydrotubation.

On laparoscopy she was found to have an absent right infundibulopelvic ligament with a torted and elongated right hydrosalpinx that extended to the left pelvis where an isolated dermoid cyst lay. This dermoid cyst was separate from the streak right ovary but there were plenty of vascular connections between this dermoid cyst and the omentum, anterior abdominal wall and bowel. A cystectomy and drainage of the right hydrosalpinx was performed.



(Left) Omental adhesions at left iliac fossa with vascularity between anterior abdominal wall and dermoid cyst

(Right) Dermoid cyst with pus and hair contents



(Left) Right tube elongated and torted many times with hydrosalpinx noted

(Right) Close up of absent right infundibulopelvic ligament and streak right ovary

## Discussion

We hypothesize that torsion may have occurred thus obliterating the infundibulopelvic ligament on the right side of our patient. This may also explain the elongated and non-patent right tube. It is interesting that the patient had no symptoms and also necrosis did not occur despite the infundibulopelvic ligament carrying the ovarian artery being the main blood supply to the ovary. We postulate that this may be because the torsion had been a slow intermittent process and along the way collateral vasculature developed resulting in the supply of blood to the dermoid cyst via the uterine artery, omentum, bowels and anterior abdominal wall.

## Conclusion

Our patient had unusual anatomy despite being asymptomatic. These findings demonstrate that diagnostic laparoscopy may be helpful in finding a cause and guiding treatment in asymptomatic patients with primary infertility.

## Reference

1. Nezhat CH, Nezhat F, Brill AI, Nezhat C. *Normal variations of abdominal and pelvic anatomy evaluated at laparoscopy*. *Obstet Gynecol*. 1999 Aug; 94(2): 238-42